

patients with inactive herpetic keratitis, and the most effective treatment regimen (dose and time before and after surgery) remains to be defined.

We recommend caution in the selection of candidates with history of herpetic keratitis for LASIK surgery. In the preoperative evaluation for refractive surgery, it is important to obtain a clinical history consistent with herpetic keratitis to identify patients at risk of reactivation—subepithelial corneal scarring is not always present. Once a patient with a known history of herpetic keratitis is identified, and in the absence of any other contraindication for LASIK, we would base our selection of the case on the following criteria: inactive disease for a minimum of 1 year, normal corneal sensitivity, normal pachymetry map excluding focal thinning, regular topography, and normal BSCVA (no opacities involving the visual axis). The patient must be informed of the risk of reactivation. Should the surgeon decide to perform LASIK, the most reasonable effective clinical strategy would be to use perioperative antiviral prophylaxis.

In accordance with previous data, the study presented offers further evidence that perioperative antiviral prophylaxis may protect the cornea from reactivation of HSV after LASIK. Nevertheless, given the limited number of cases and the lack of a control group, further studies are necessary to establish the need for perioperative systemic antiviral prophylaxis in all patients and the optimum treatment regimen as well as the safety and efficacy of LASIK in this patient population.

## REFERENCES

- McDonnell PJ, Moreira H, Clapham TN, Munnerlyn CR. Photorefractive keratectomy for astigmatism: initial clinical results. *Arch Ophthalmol*. 1991;109:1370-1373.
- Pepose JS, Laycock KA, Miller JK, Chansue E, Lenze EJ, Gans LA, Smith ME. Reactivation of latent herpes simplex virus by excimer laser photokeratectomy. *Am J Ophthalmol*. 1992;114:45-50.
- Vrabec MP, Anderson JA, Rock ME, Binder PS, Steinert RF, Durrie DS, Chase DS. Electron microscopic findings in a cornea with recurrence of herpes simplex keratitis after excimer laser phototherapeutic keratectomy. *CLAO J*. 1994;20:41-44.
- Davidorf JM. Herpes simplex keratitis after LASIK. *J Refract Surg*. 1998;14:667.
- Dhaliwal DK, Barnhorst DA Jr, Romanowski E, Rehkopf PG, Gordon YJ. Efficient reactivation of latent herpes simplex virus type 1 infection by excimer laser keratectomy in the experimental rabbit ocular model. *Am J Ophthalmol*. 1998;125:488-492.
- Dhaliwal DK, Romanowski EG, Yates KA, Hu D, Goldstein M, Gordon YJ. Experimental laser-assisted in situ keratomileusis induces the reactivation of latent herpes simplex virus. *Am J Ophthalmol*. 2001;131:506-507.
- Dhaliwal DK, Romanowski EG, Yates KA, Hu D, Mah FS, Fish DN, Gordon YJ. Valacyclovir inhibition of recovery of ocular herpes simplex virus type 1 after experimental reactivation by laser in situ keratomileusis. *J Cataract Refract Surg*. 2001;27:1288-1293.
- Dhaliwal DK, Romanowski EG, Yates KA, Barnhorst DA, Goldstein MH, Deeter R, Fish D, Gordon YJ. Valacyclovir inhibits recovery of ocular HSV-1 after experimental reactivation by excimer laser keratectomy. *Cornea*. 1999;18:693-699.
- Jarade EF, Tabbara KF. Laser in situ keratomileusis in eyes with inactive herpetic keratitis. *Am J Ophthalmol*. 2001;132:779-780.
- Cunningham ET. Diagnosing and treating herpetic anterior uveitis. *Ophthalmology*. 2000;107:2129-2130.

## NeuroVision Treatment for Low Myopia Following LASIK Regression

Kooi Ling Lim, BOptom(Hons); Han Bor Fam, MD

### ABSTRACT

**PURPOSE:** To evaluate a novel non-surgical method for improving vision in a refractive surgery patient.

**METHODS:** A 45-year-old man who had undergone LASIK 5 years previously presented with blurred distance vision. Unaided vision in the right eye was 20/32<sup>-2</sup> and 20/20 in the left eye. He enrolled for NeuroVision treatment (NeuroVision Pte Ltd, Singapore), a computer-based interface in which a repetitive set of visual exercises is performed for 10 to 12 weeks.

**RESULTS:** After 35 sessions, unaided visual acuity in the right eye was 20/16<sup>-3</sup> and 20/20<sup>-1</sup> in the left eye, representing 2.8 lines of improvement in the right eye and 1.6 lines in the left eye.

**CONCLUSIONS:** NeuroVision, a noninvasive treatment based on the concept of perceptual learning, is a benefit in cases in which surgical enhancement is not recommended. [*J Refract Surg*. 2006;22:406-408.]

A recent study of common complaints of dissatisfied refractive surgery patients showed that 59% were unhappy because of blurred distance vision and 43.5% because of poor night vision.<sup>1</sup> A novel method for improving vision in these post-refractive surgery patients without further surgery is being tested using NeuroVision (NeuroVision Pte Ltd, Singapore). NeuroVision is a computer-based treatment interface where a repetitive set of visual exercises is performed

From iLaser Centre, Island Hospital, Penang, Malaysia (Lim); and The Eye Institute, Tan Tock Seng Hospital, Singapore (Fam).

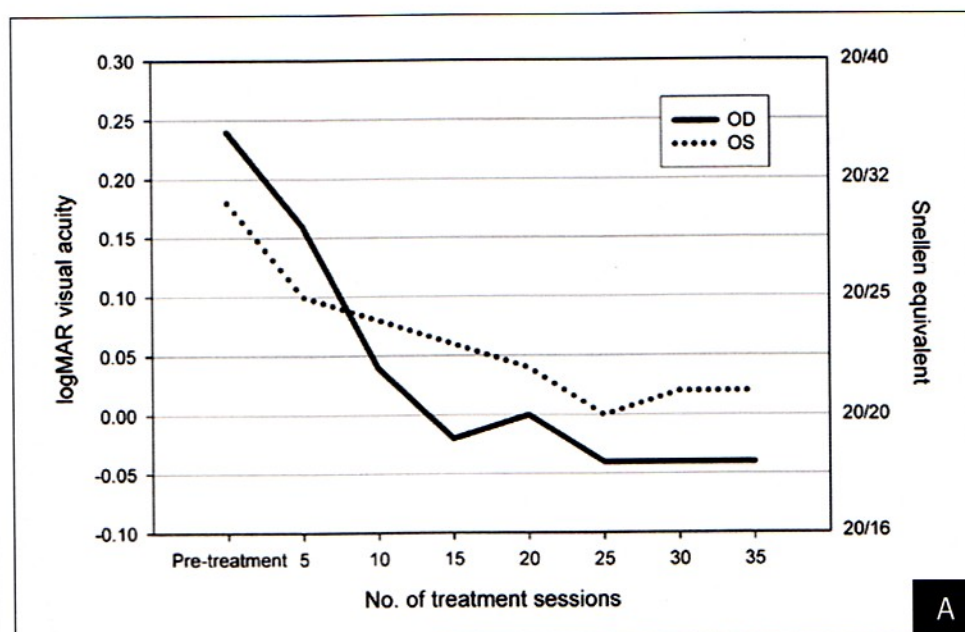
The authors have no financial interest in the materials presented herein.

Correspondence: Kooi Ling Lim, BOptom(Hons), iLaser Centre, 3rd Fl Island Hospital, 308 Macalister Rd, 10450 Penang, Malaysia. E-mail: kooiling@islandhospital.com

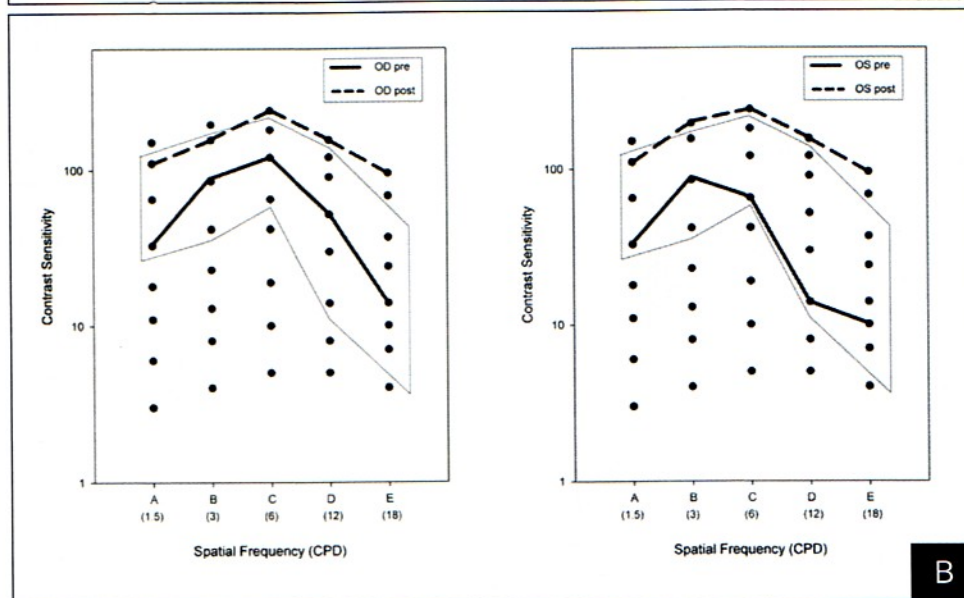
Received: August 19, 2005

Accepted: November 19, 2005





**Figure. A)** Change in unaided visual acuity and **B)** contrast sensitivity during the NeuroVision treatment.



for 10 to 12 weeks. It is founded on the concept of perceptual learning previously described for the treatment of amblyopia.<sup>2,3</sup>

### CASE REPORT

A healthy 45-year old man underwent LASIK in November 2000 to correct  $-9.50 -1.00 \times 180$  (20/20) in the right eye and  $-9.00 -1.25 \times 175$  (20/20) in the left eye with targeted emmetropia in both eyes. In January 2005, the patient returned complaining of blurred distance vision. Unaided vision was 20/32<sup>-2</sup> (0.24 logMAR) in the right eye and 20/40 (0.30 logMAR) in the left eye with a refraction of  $-0.25 -0.75 \times 155$  (20/20) in the right eye and  $-1.00 -0.50 \times 50$  (20/20)

in the left eye. Although presbyopic, he did not have any problems with unaided near vision but had begun using glasses when driving at night 1 year after the initial LASIK. Cycloplegic refraction did not reveal any accommodative element in the residual myopia. The patient underwent a full ophthalmic assessment to ensure that his eyes were free from pathology. A LASIK enhancement was discussed and the patient was discouraged from correcting his unintended monovision, as it would lead to loss of near vision.

The patient enrolled for the NeuroVision treatment and upon completing treatment (after 35 sessions) in early June 2005, his unaided visual acuity was 20/16<sup>-3</sup> ( $-0.04$  logMAR) in the right eye and 20/20<sup>-1</sup> (0.02 log-



MAR) in the left eye with no change in the manifest or cycloplegic refraction (Fig). This represents 2.8 lines of visual improvement in the right eye and 1.6 lines in the left eye. The repeatability (95% limits of agreement) of this set of logMAR charts in our clinic setting was previously tested and found to be 0.09 logMAR units.<sup>4</sup> This shows the improved visual acuity reported by the patient is actual improvement and not an artifact of noise in the visual acuity measurements. The contrast sensitivity function measured with the Sine Wave Contrast Test (Stereo Optical Co Ltd, Chicago, Ill) also showed improvement at every measured spatial frequency (see Fig). The patient reported marked improvement in photopic and mesopic vision and no longer relied on glasses.

### DISCUSSION

As described in the literature on perceptual learning,<sup>5</sup> in neurons in the primary visual cortex, stimuli present within the receptive field can be facilitated or suppressed by other stimuli present outside the receptive field. Modulation of neuronal responses by stimuli falling outside the receptive field represents a neural mechanism for enhancing visual perception. By repetitively stimulating this neural mechanism, the enhanced visual perception may be transferred to other higher-level visual tasks such as visual acuity and contrast sensitivity.

The availability of a noninvasive treatment to improve unaided visual acuity and contrast sensitivity in patients following refractive surgery is a benefit to any refractive surgery practice especially in cases where enhancement is contraindicated.

### REFERENCES

1. Jabbur NS, Sakatani K, O'Brien TP. Survey of complications and recommendations for management in dissatisfied patients seeking a consultation after refractive surgery. *J Cataract Refract Surg*. 2004;30:1867-1874.
2. Levi DM, Polat U. Neural plasticity in adults with amblyopia. *Proc Natl Acad Sci USA*. 1996;93:6830-6834.
3. Karni A, Sagi D. Where practice makes perfect in texture discrimination: evidence for primary visual cortex plasticity. *Proc Natl Acad Sci USA*. 1991;88:4966-4970.
4. Fam HB, Lim KL. Effect of higher-order wavefront aberrations on binocular summation. *J Refract Surg*. 2004;20:S570-S575.
5. Polat U, Mizobe K, Pettet MW, Kasamatsu T, Norcia AM. Colinear stimuli regulate visual responses depending on cell's contrast threshold. *Nature*. 1998;391:580-584.

## Photorefractive Keratectomy in Megalophthalmos Anterior

Éva Gallyas, MD; Vanda Hidasi, MD, PhD; István Ferincz; Lajos Kolozsvári, MD, PhD

### ABSTRACT

**PURPOSE:** To evaluate the results of photorefractive keratectomy (PRK) for the correction of myopia and myopic astigmatism in megalophthalmos anterior.

**METHODS:** Four eyes of two brothers with megalophthalmos anterior were treated with PRK. In patient 1, best spectacle-corrected visual acuity (BSCVA) was 20/20 in both eyes with a refraction of  $-4.50 -4.50 \times 180^\circ$  in the right eye and  $-3.75 -3.00 \times 175^\circ$  in the left eye. In patient 2, BSCVA was 20/25 in both eyes with a refraction of  $-4.25 \times 166^\circ$  in the right eye and  $+0.50 -4.00 \times 175^\circ$  in the left eye.

**RESULTS:** Topographic map, slit-lamp, ultrasound biomicroscopy, and postoperative course (no progression), supported with vectorial analysis, demonstrated megalophthalmos anterior. During 24-month follow-up, mild haze was observed and BSCVA was maintained.

**CONCLUSIONS:** Myopia and astigmatism are often observed in this type of nonprogressive corneal dysgenesis. Based on this fact and our results, we recommend PRK in cases of megalophthalmos anterior. [*J Refract Surg*. 2006;22:408-411.]

Megalophthalmos anterior is a distinctive type of corneal dysgenesis. This group of disorders can best be described as a disturbance in the growth and development of neural crest cells. A large myopic astigmatic refractive error often results from the abnormal optical architecture.<sup>1</sup> Corneal thickness and endothelial cell density are generally normal. The iris root may exhibit transillumination defects as

From KLIN Ophthalmologic Ltd (Gallyas, Hidasi); the Department of Ophthalmology, University of Szeged, Faculty of Medicine, Szeged (Gallyas, Kolozsvári); and Focus Medical (Ferincz), Budapest, Hungary.

The authors have no proprietary interest in the materials presented herein.

The authors thank András Szabó, PhD, for the software and his assistance.

Correspondence: Éva Gallyas, MD, KLIN Ophthalmologic Ltd, Korányi fasor 10-11, 6701 - Szeged, Hungary. Tel: 3662 545092; Fax: 3662 544573; E-mail: gallyas@ophth.szote.u-szeged.hu

Received: April 19, 2005

Accepted: October 3, 2005